

Papillary Lesions of Oral Mucosa II

Diffuse Papillary and Verrucous Lesions

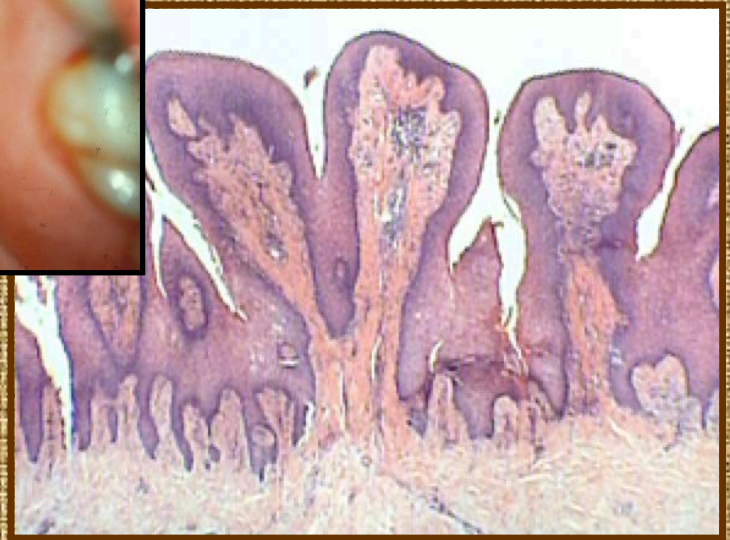
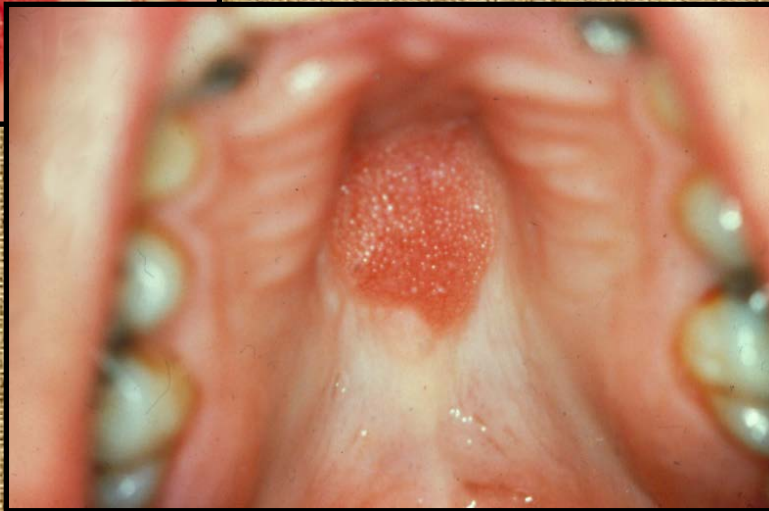
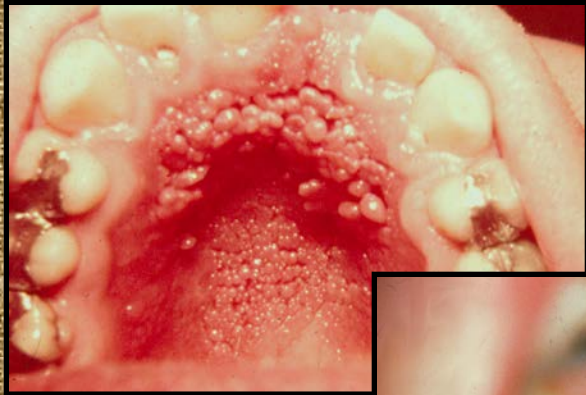
- Denture Papillary Hyperplasia
- Condyloma acuminatum
- Focal Epithelial Hyperplasia
- Multiple Endocrine Neoplasia III
- Proliferative Verrucous Leukoplakia
- Acanthosis Nigricans
- Focal Dermal Hypoplasia
- Keratosis Follicularis

Papillomatosis

Inflammatory Papillary Hyperplasia

- Palatal lesions under denture
- Extend only within denture bearing regions
- Negative pressure relief zone
- Secondary candidiasis
- Excision, new denture

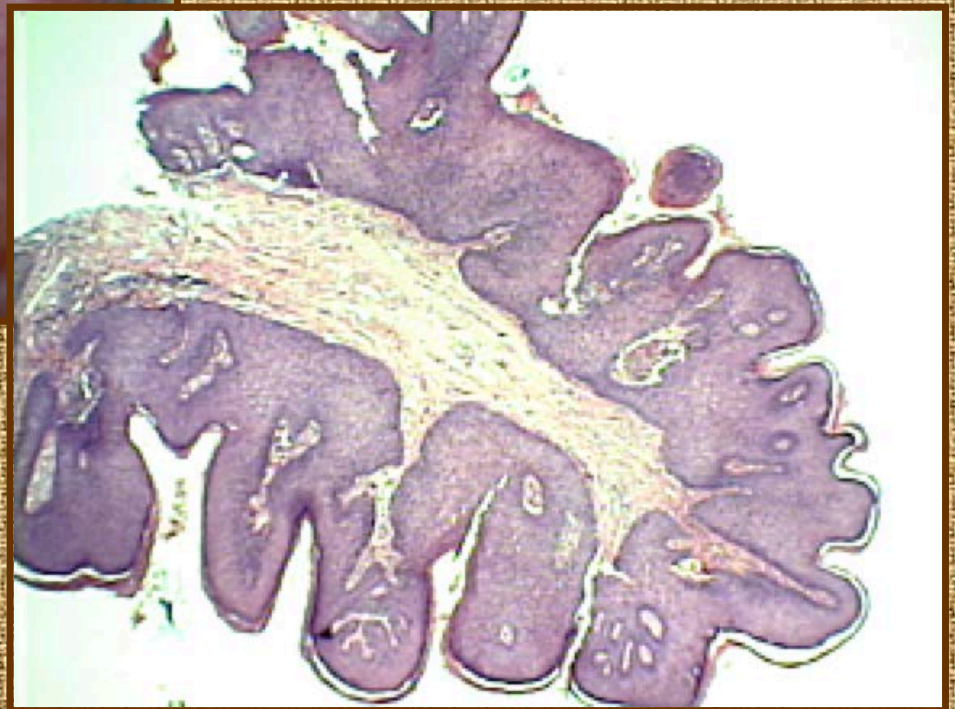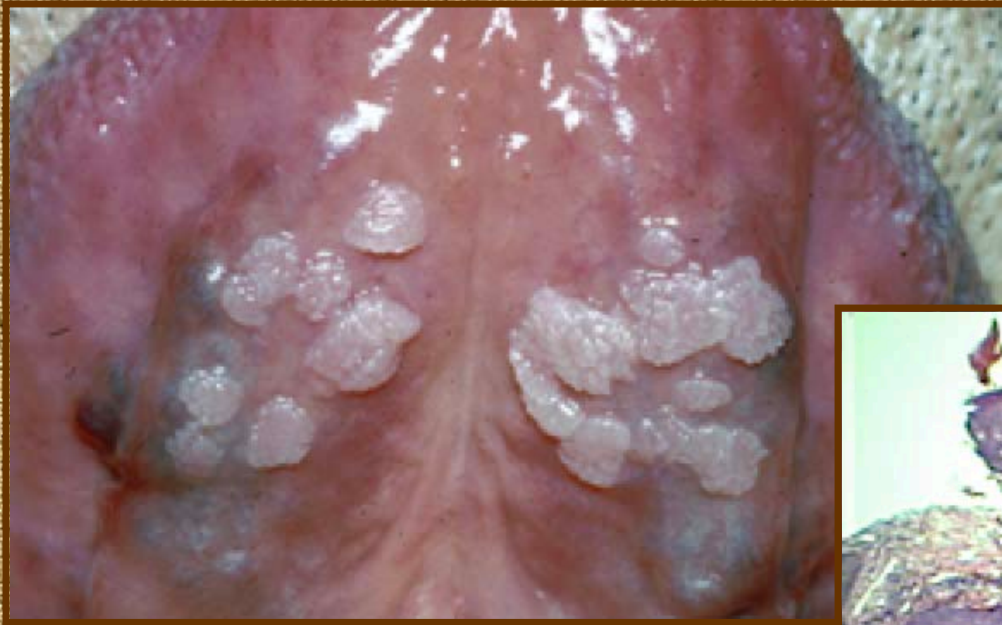Denture Papillomatosis



Condylomata

- Multifocal Papillary Lesions
- White or coral pink
- Intervening normal mucosa
- HPV 6, 11
- Excision, Laser surgery

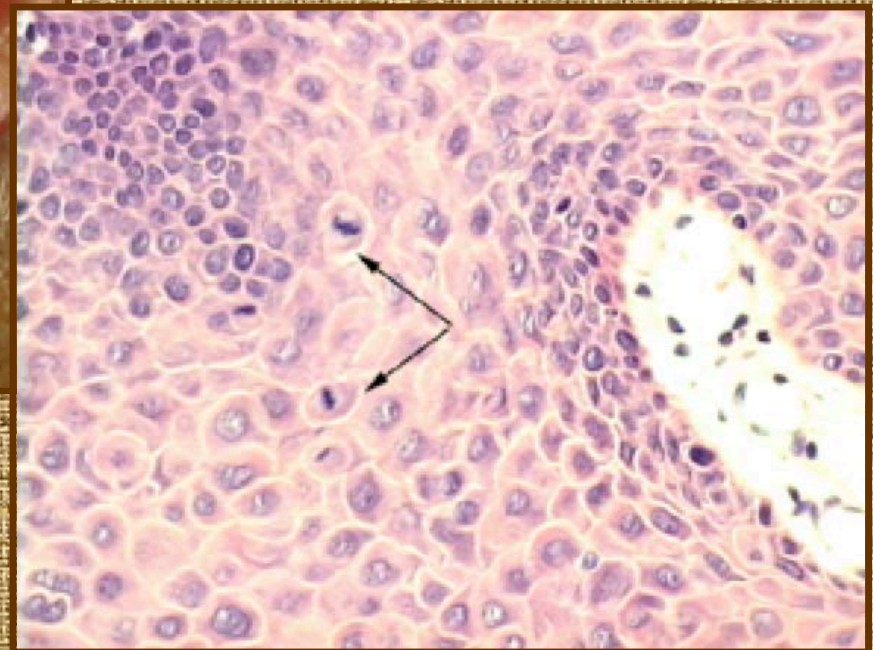
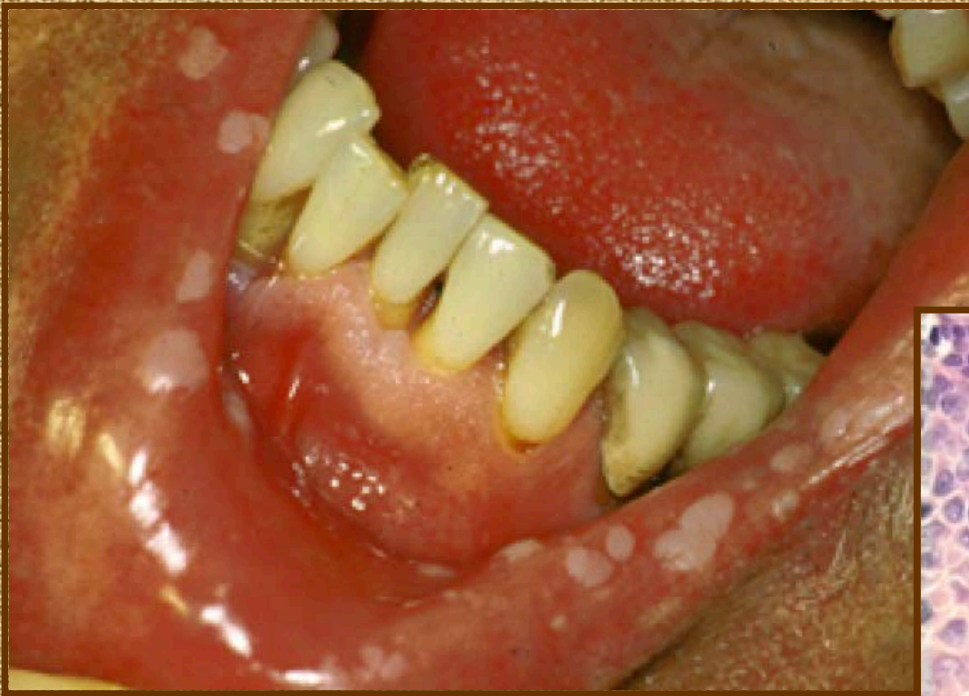Multifocal Condylomas



Focal Epithelial Hyperplasia

- Childhood, Teen onset
- Multiple “fibroma-like” papules
- Lips and Buccal Mucosa
- Spontaneous resolution 3-12 months
- HIV associated condylomas may look similar to FEH
- HPV 13, 32
- Mitosoid Viral Inclusions

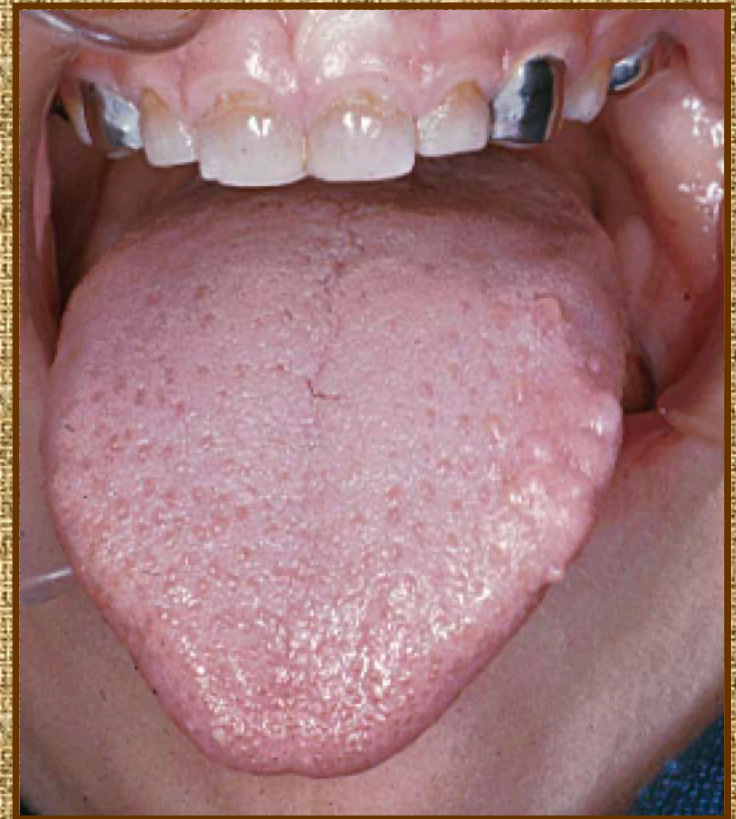
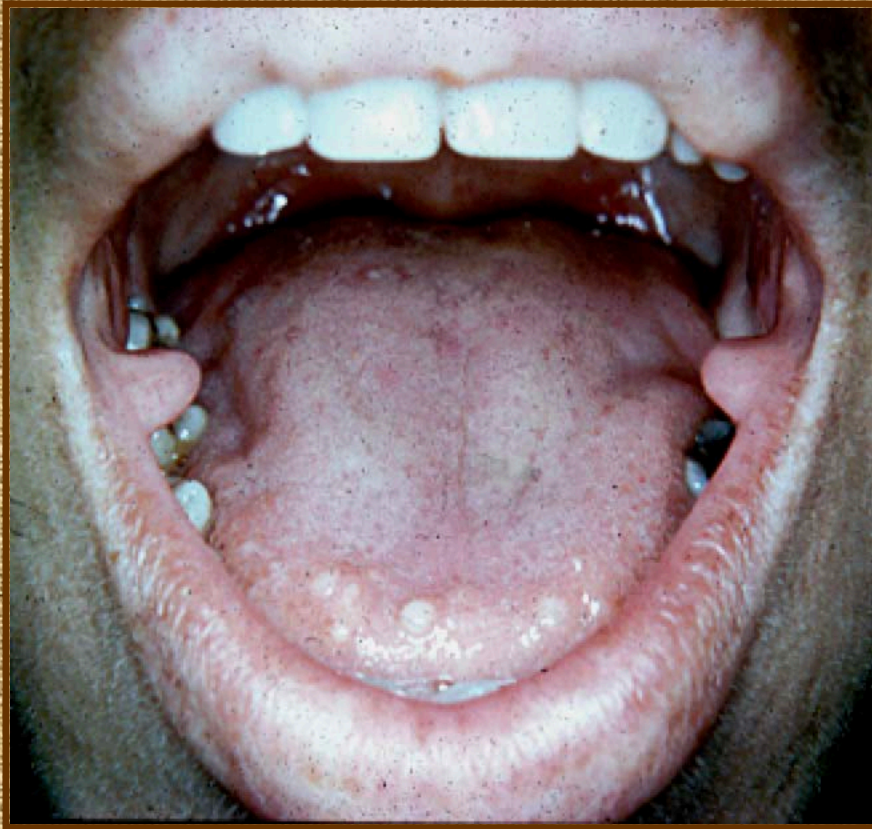
Focal Epithelial Hyperplasia (Heck's Disease)



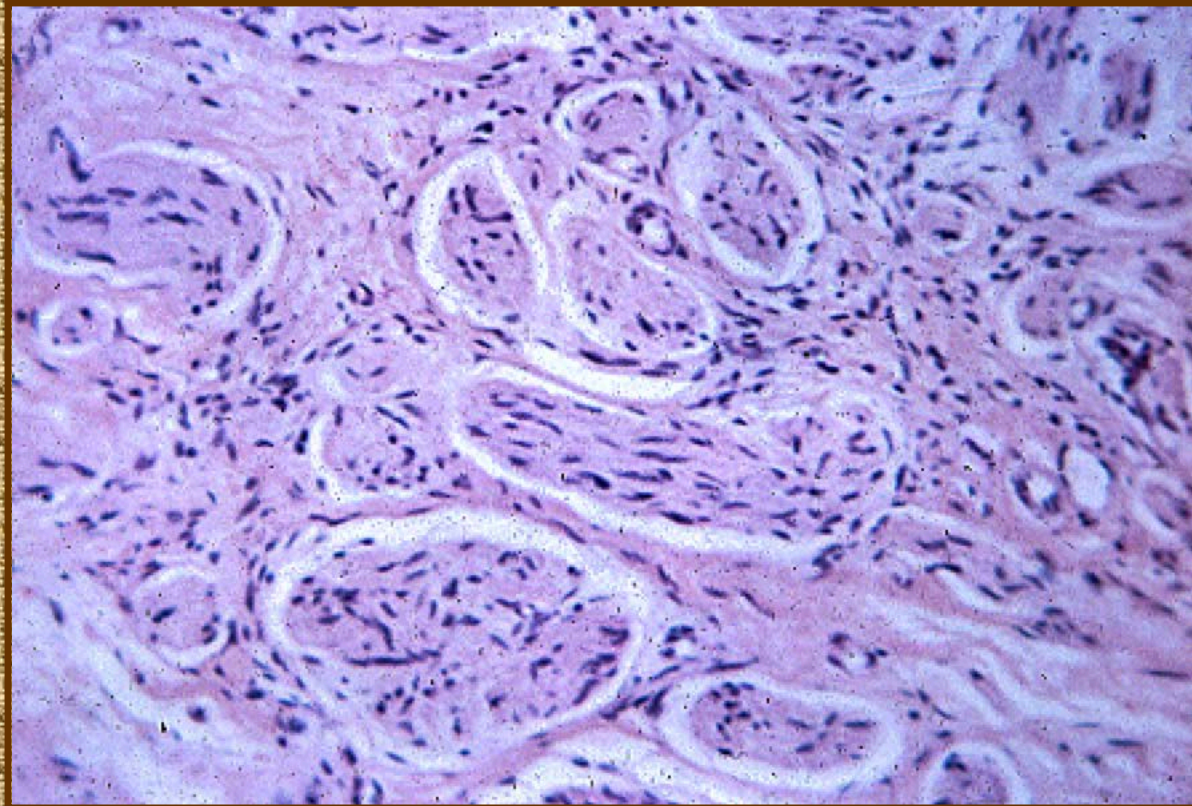
Multiple Endocrine Neoplasia III (MEN)

- Pheochromocytoma
- Medullary carcinoma of the thyroid
- Teen onset
- Multiple nodular mucosal neuromas
 - Lips
 - Eyelids
- Mutated gene

MEN III, Mucosal Neuromas



MEN III, Neuroma

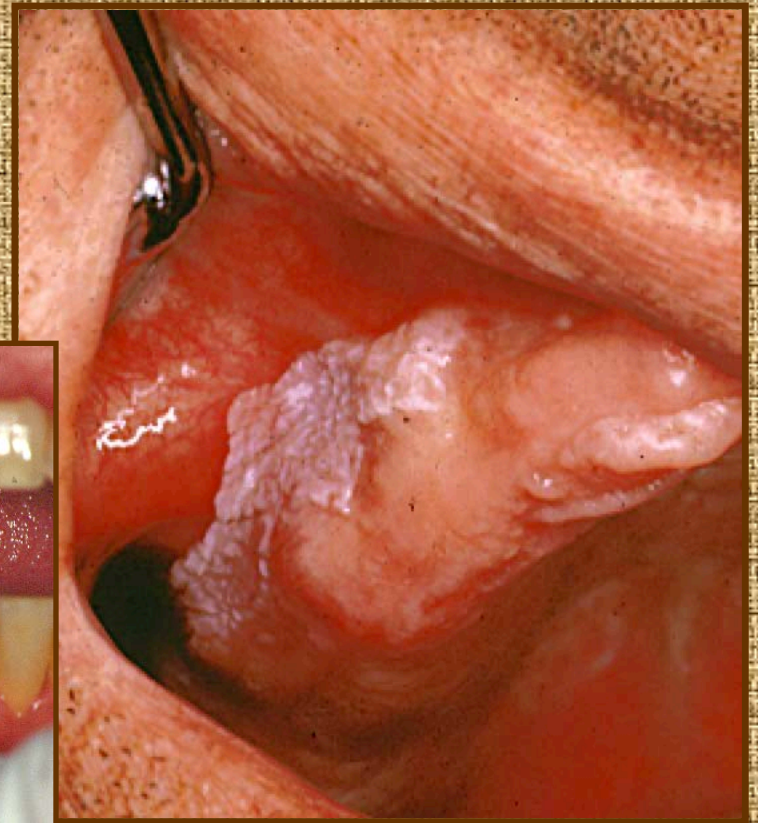
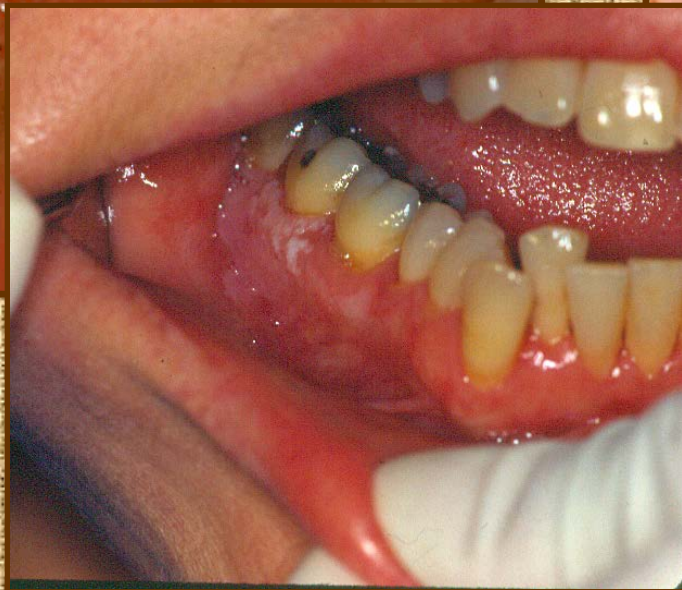
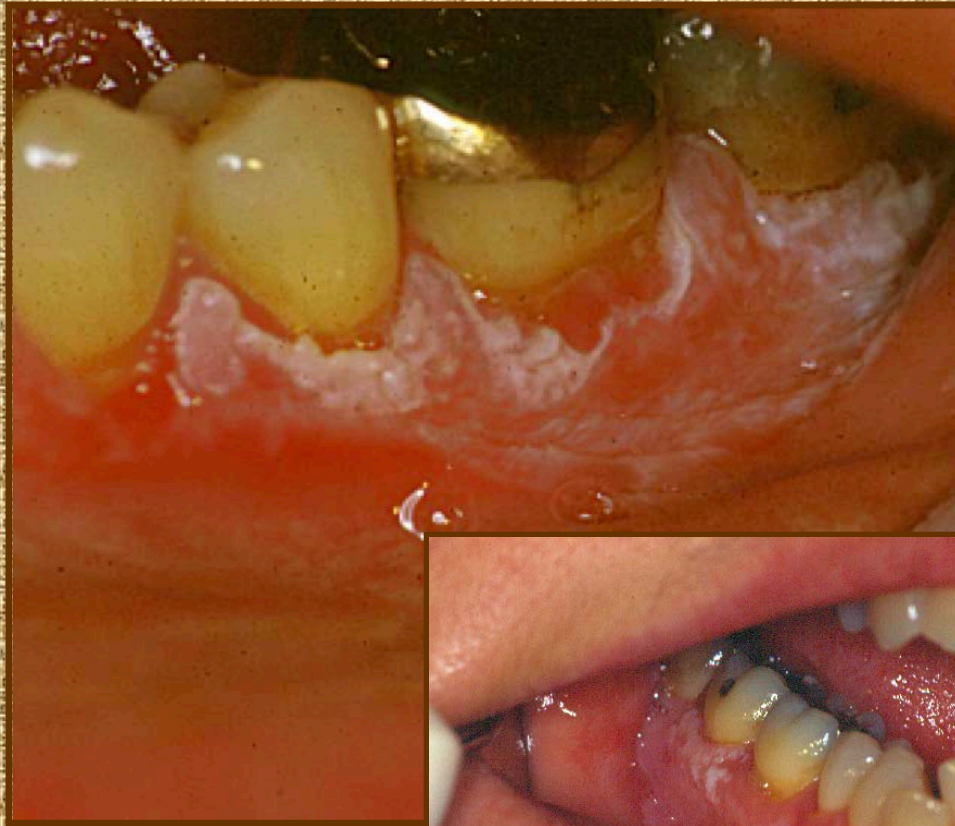
Proliferative Verrucous Leukoplakia (PVL)

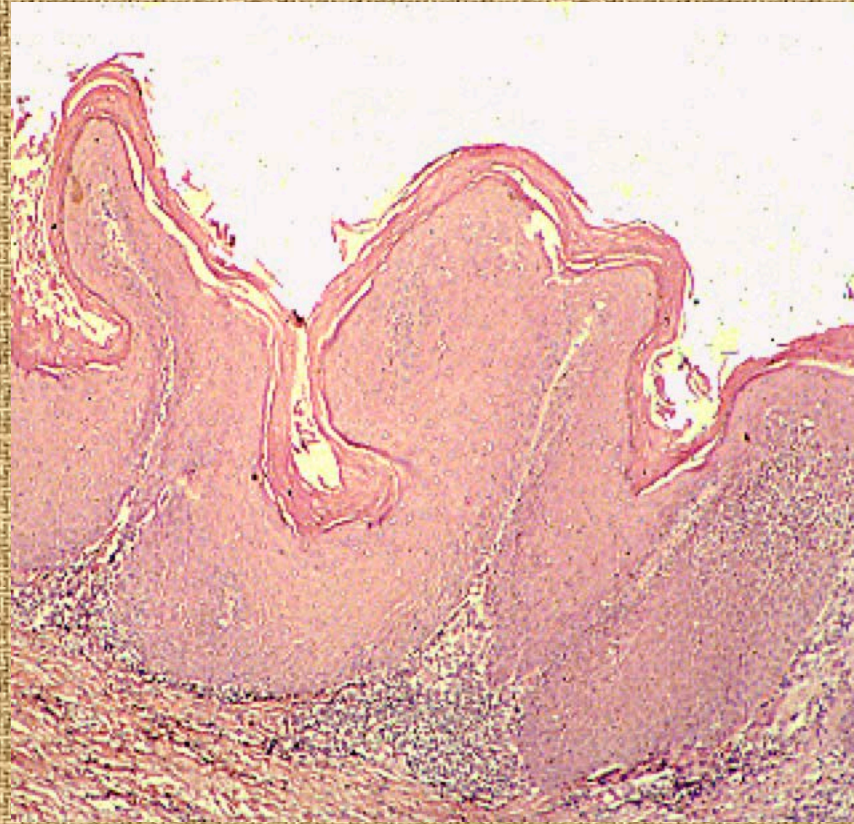- Elderly
- Females > Males
- Alveolar Ridge/Vesibule
- Progressive lateral spread over years
- A spectrum of histologic variants
 - Atypical verrucous hyperplasia
 - Verrucous carcinoma
 - Papillary squamous cell carcinoma
 - Invasive squamous cell carcinoma

Progressive Temporal Change in PVL

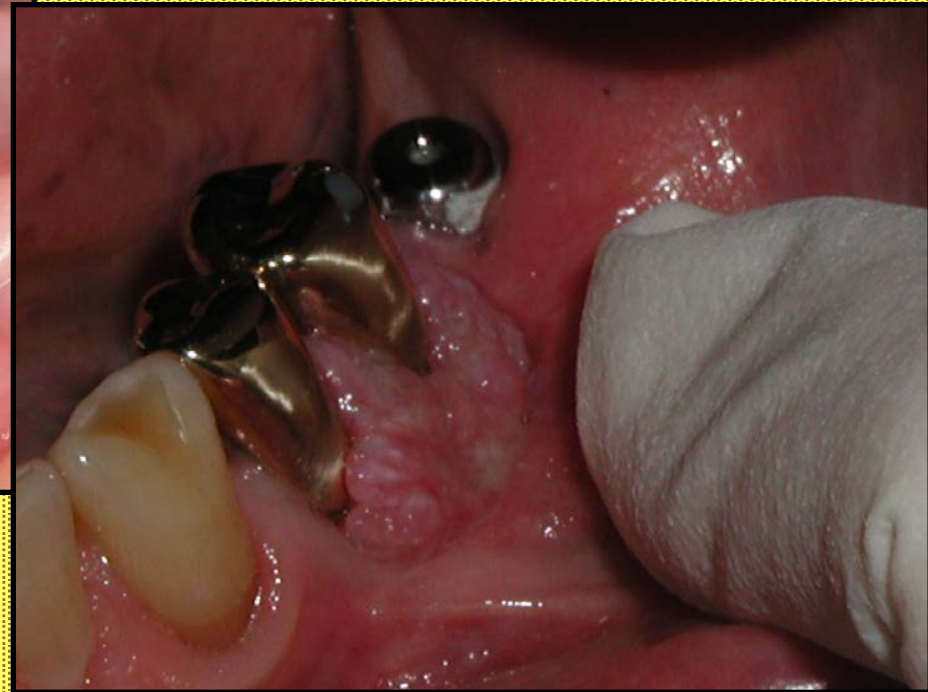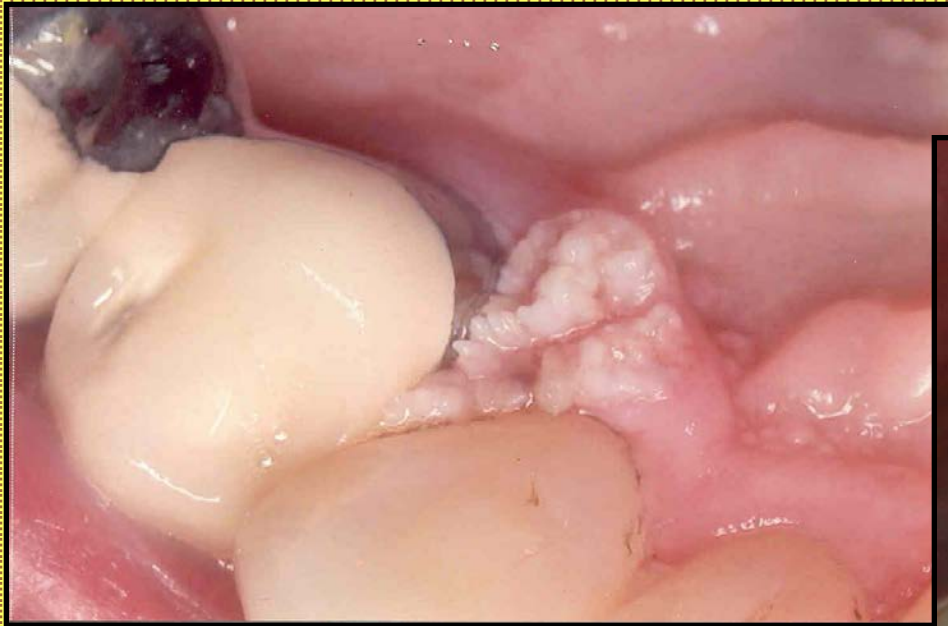
Proliferative Verrucous Leukoplakia



PVL, Atypical Verrucous Hyperplasia

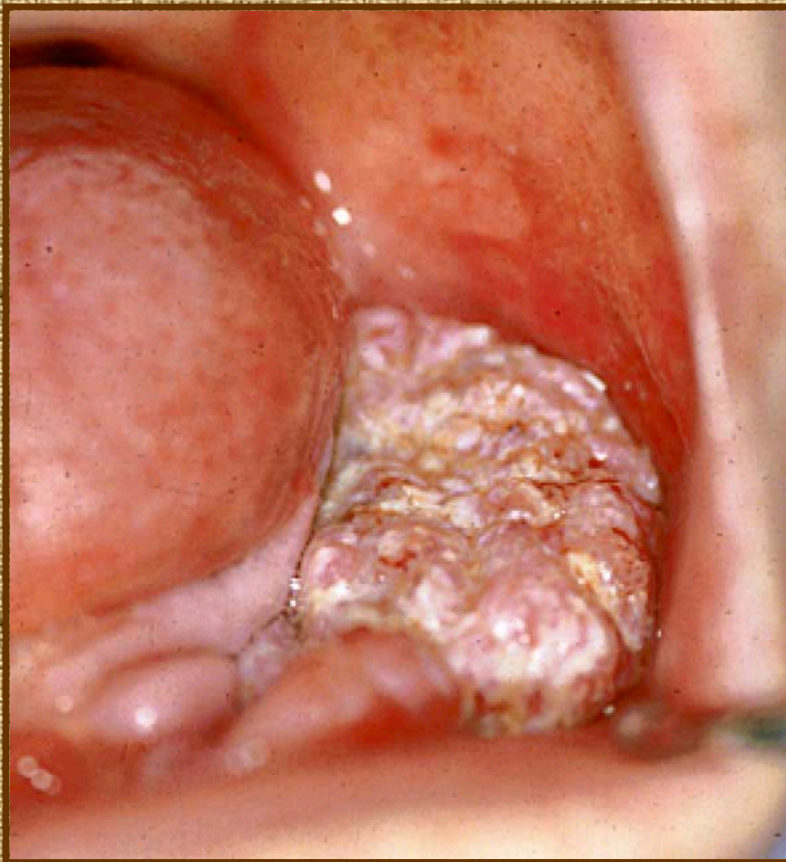


Atypical Verrucous Hyperplasia

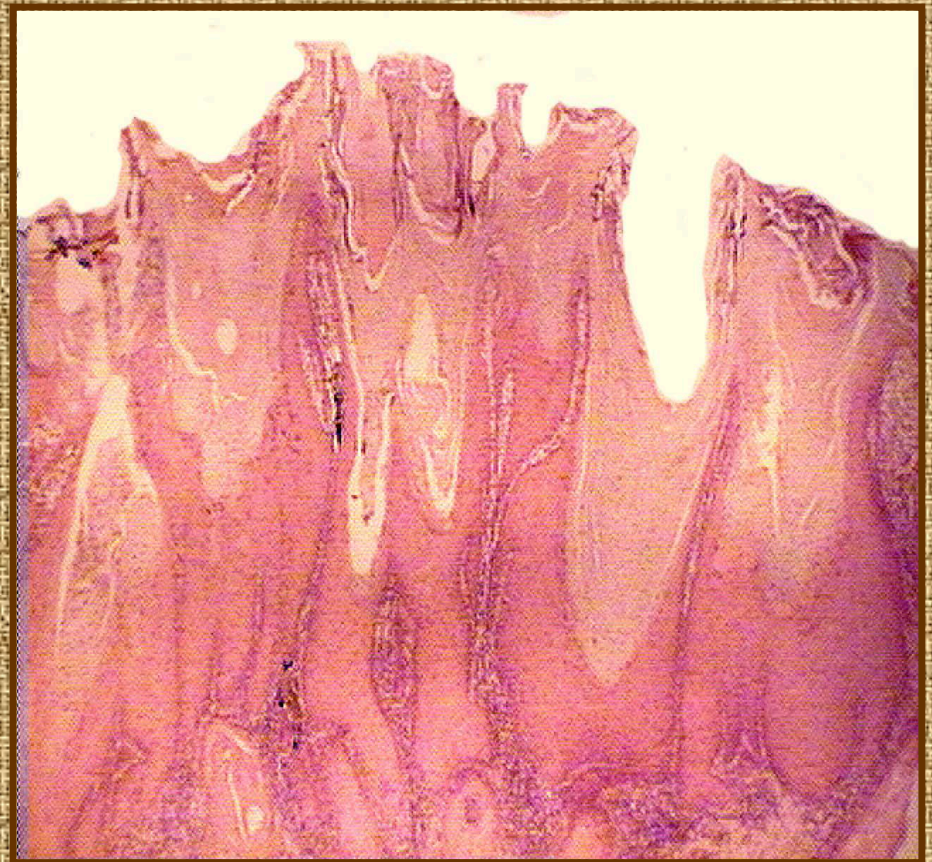


Verrucous Carcinoma

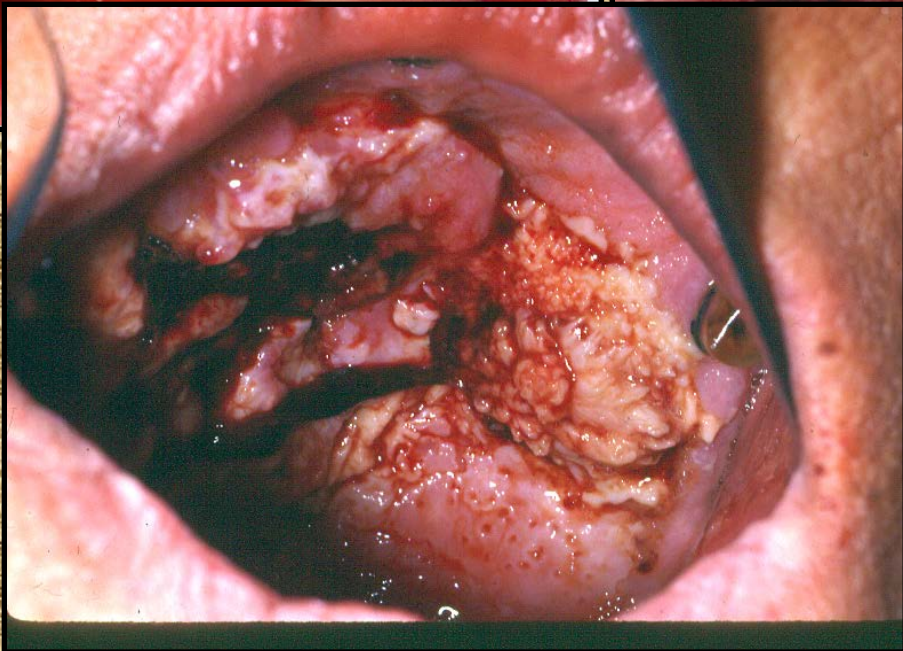
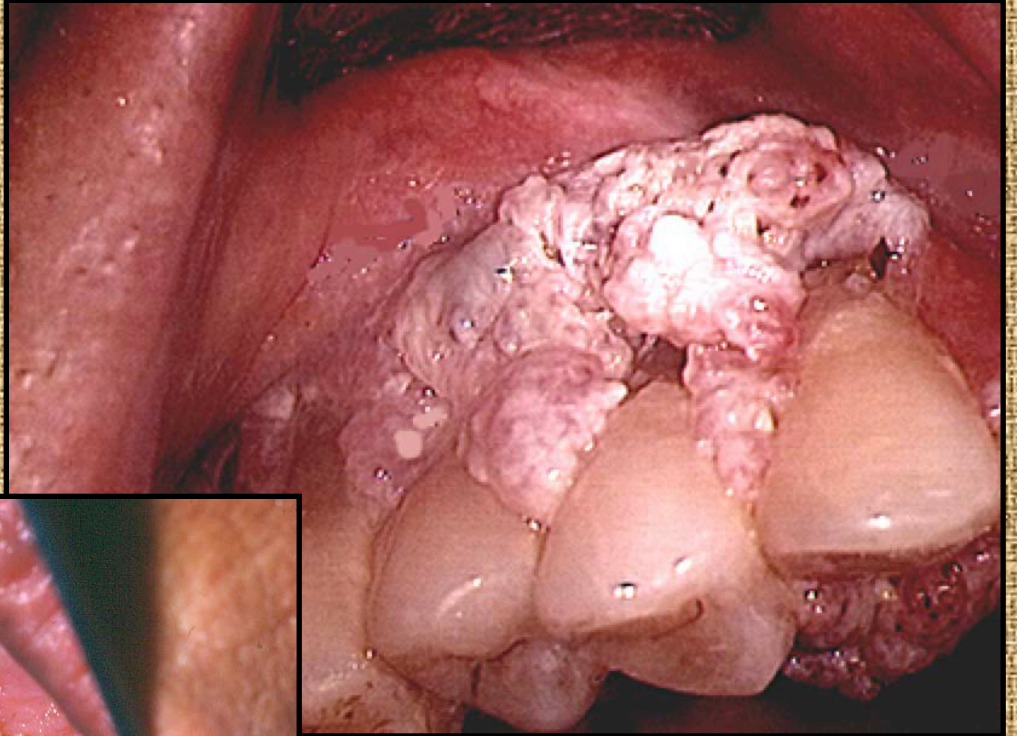
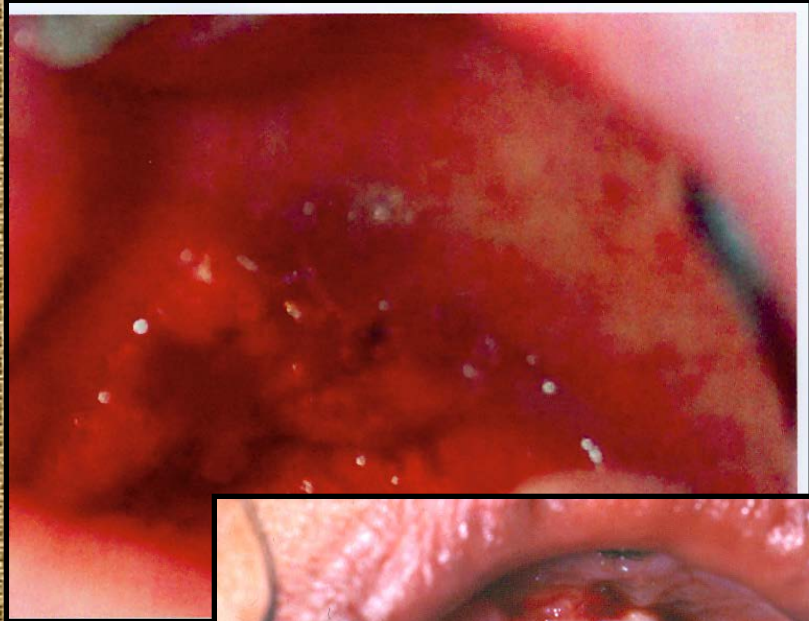
- Clinical



- Histopathology



PVL, Papillary Squamous Cell Carcinoma



Acanthosis Nigricans

- Lips and commisures
- Pebbly surface
- Variable pigmentation
- Two subtypes
 - Benign
 - Malignant (adenocarcinoma, gut)
- Papillomatosis, basilar melanosis

Acanthosis Nigricans

Focal Dermal Hypoplasia

- Collagen defect in dermis
- Soft fibrous tumors of skin
- Papillary lesions of oral mucosa
- Strabismus
- Mental retardation

Focal Dermal Hypoplasia

Keratosis Follicularis (Darier-White disease)

- Defect in keratinization
- Orange keratotic papules of skin
- Cobblestone appearing lesions of oral mucosa
- Microscopic
 - Hyperkeratosis
 - Acantholysis
 - Dyskeratosis (corps ronds and grains)

Keratosis Follicularis