

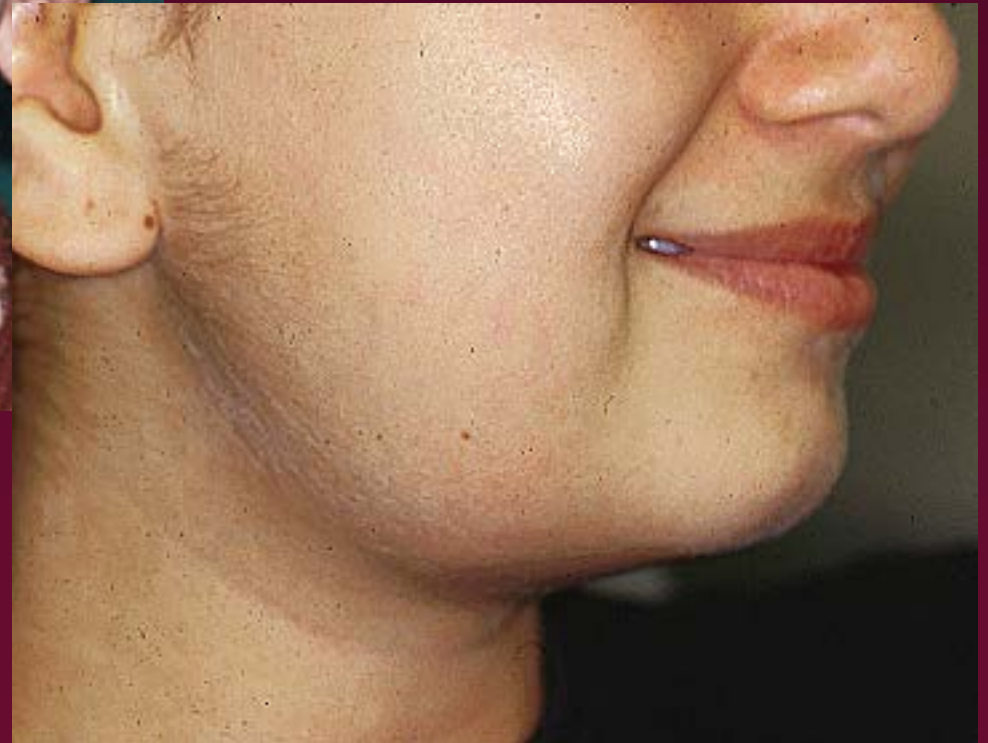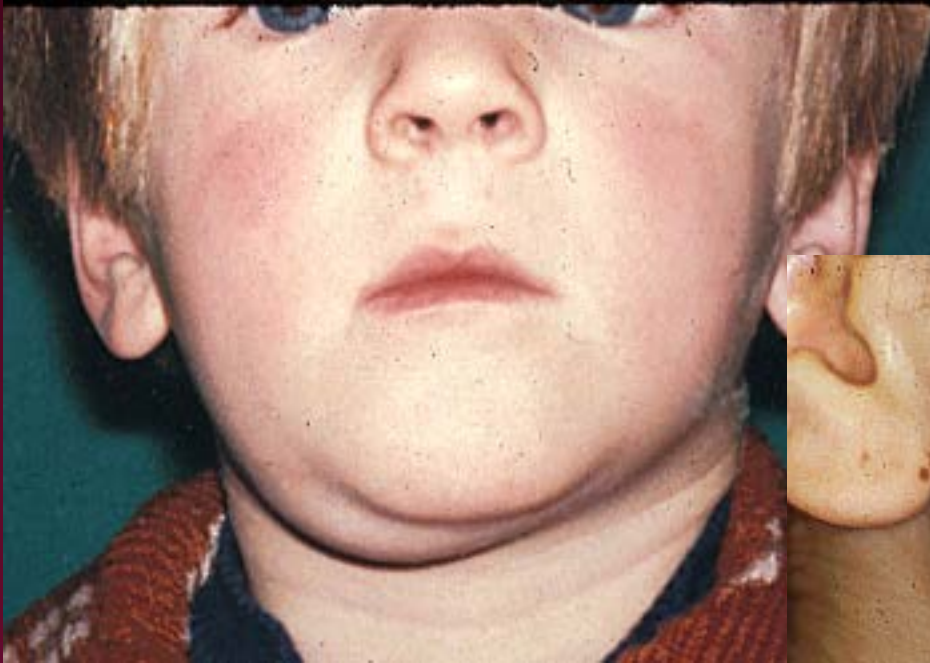Cortical Redundancy

- Proliferative Periostitis
- Ewing's Sarcoma
- Infantile Cortical Hyperostosis

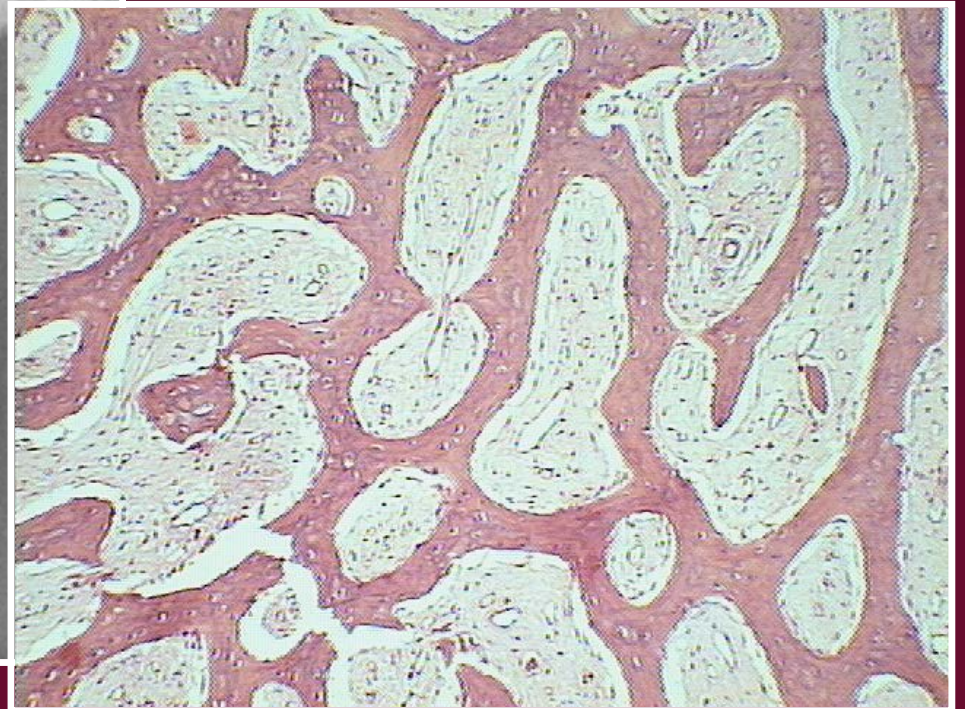
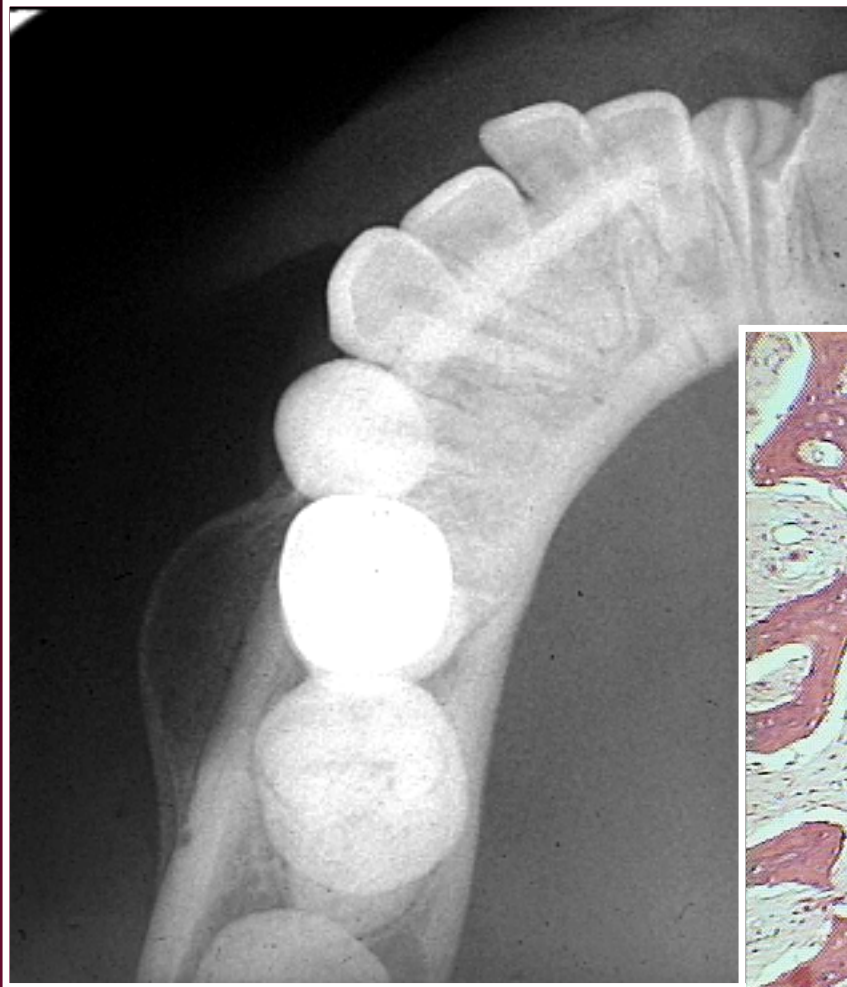
Garre's Proliferative Periostitis

- Accompaniment to Chronic Sclerosing Osteomyelitis
- Children
- Body of Mandible
- Episodic Pain
- Ground Glass Opacity

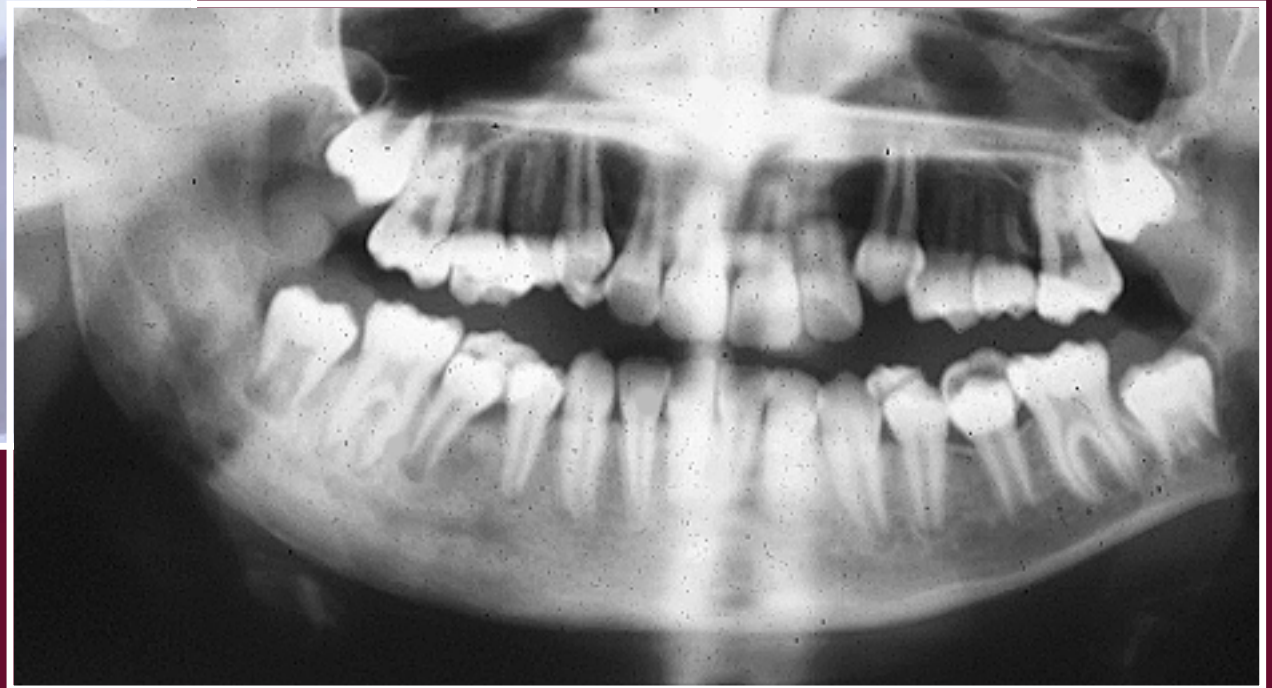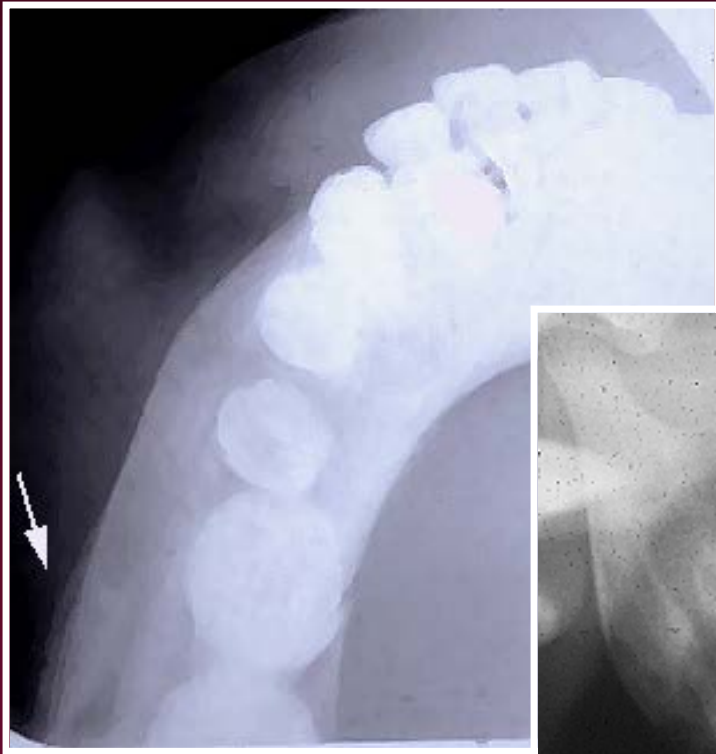
Garre's Proliferative Periostitis



Garre's Periostitis



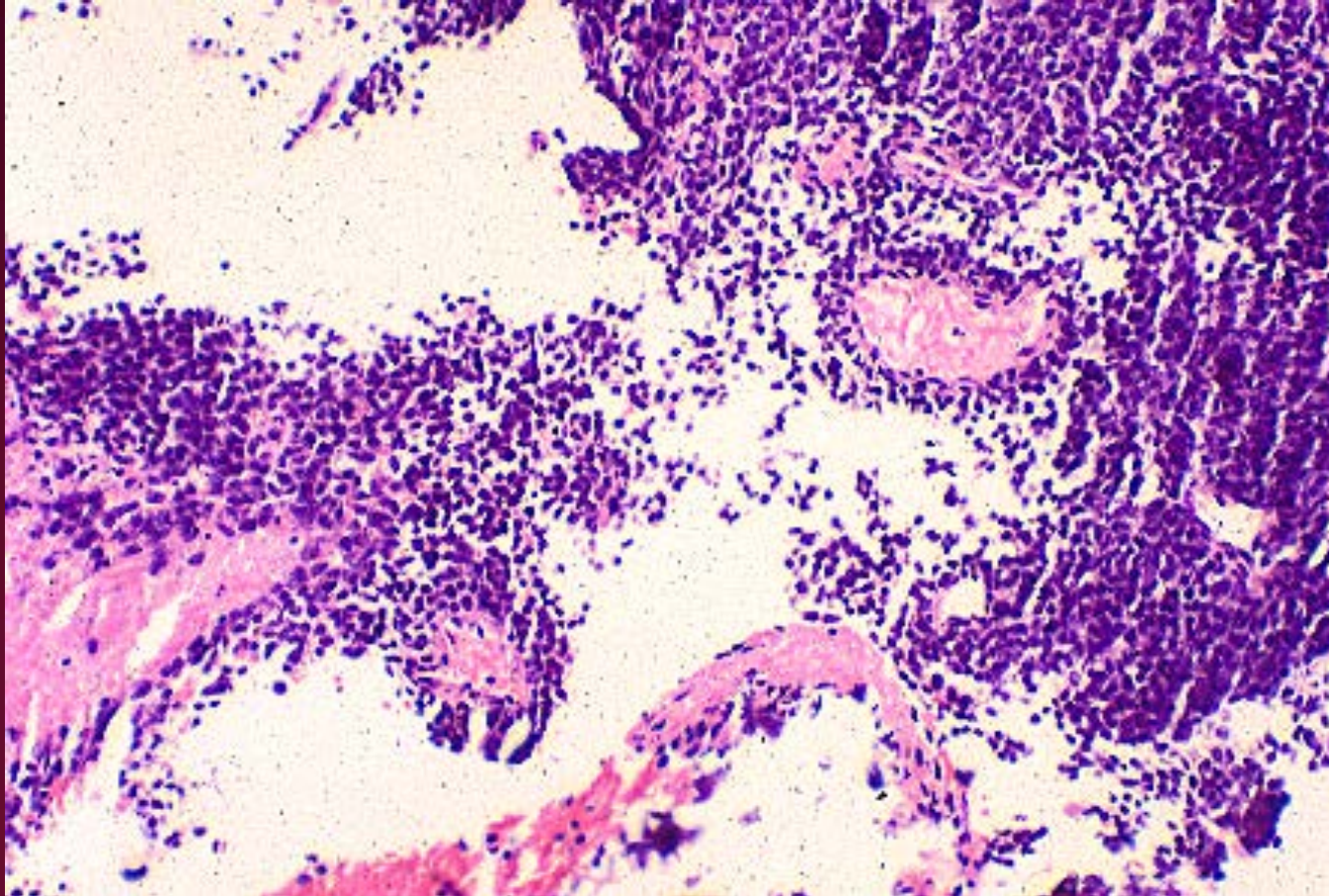
Garre's Proliferative Periostitis



Ewing's Sarcoma

- Extremely Rare in the Jaws
- Round Primitive Cell
- Intraosseous with cortical onion skinning
- Chemotherapy

Ewing's Sarcoma



Infantile Cortical Hyperostosis

- Caffey Disease
- Colic, normal accelerated bone growth among infants
- symmetrical cortical lesions

Infantile Cortical Hyperostosis

