

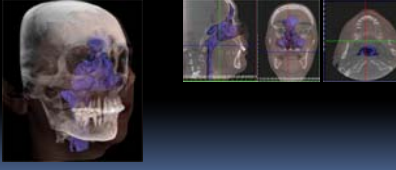
PACIFIC Western U. Oregon School of Dentistry

UPPER AIRWAY ANATOMY AND PATHOLOGY



David C. Hatcher, DDS, MS, MRCO (C)
Oral and Maxillofacial Radiologist

AIRWAY ASSESSMENT




SMALL AIRWAY
What Happened?

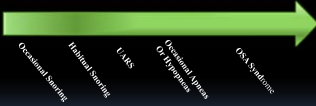
Airway Anatomy & Pathology

Sleep Disordered Breathing (SDB)

- Abnormal Respiratory Pattern During Sleep
- Snoring
- Upper Airway Resistance Syndrome
- Obstructive Sleep Apnea Syndrome
- Obesity-Hypoventilation Syndrome

UOP School of Dentistry

Increasing Upper Airway Collapsibility



UOP School of Dentistry

Polysomnography (PSG)

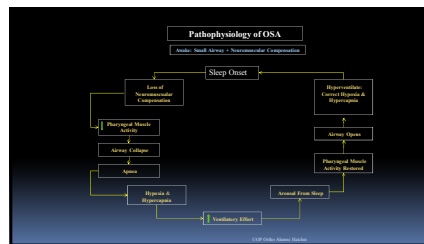
- Apnea Hypopnea Index (AHI)
 - Apnea = Cessation of Airflow > 10 seconds
- Hypopnea = Decrease in Airflow by > 30% for > 10 Seconds
 - Associated with Drop SaO₂ by > 3%
- AHI = A+H / Hour Sleep
 - > 5 Abnormal

UOP School of Dentistry

Obstructive Sleep Apnea

- Recurrent Collapse of Airway During Sleep
- Abnormal AHI with Symptoms
 - Mild OSA- 5-15 AHI Events/Hour
 - Mod. OSA- 16-30 AHI Events/Hour
 - Sev. OSA- > 30 AHI Events/Hour

UOP School of Dentistry




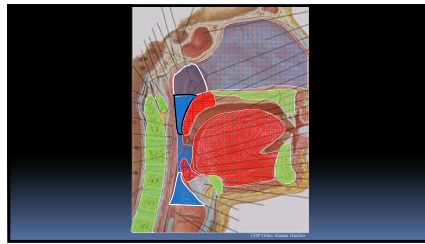
Role of Anatomy

- Abnormal Upper Airway Anatomy
- Increase Resistance
- Turbulent Air Flow
- Increases Collapsibility

UOP School of Dentistry

OSA

- Related to Abnormal Timing of Upper Airway Dilator Muscle Contraction
- Normally Dilator Muscles Contract BEFORE Diaphragm & Accessory Inspiratory Muscles Move OR it will Create a Negative Pressure Leading to Airway Collapse
- Requires Good Neurological System

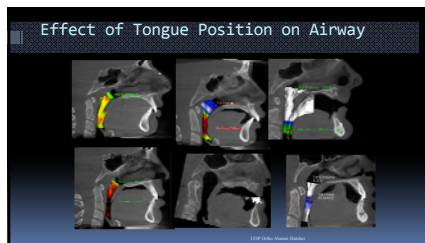



Airway Metric Analysis

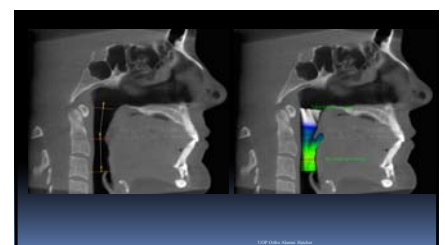
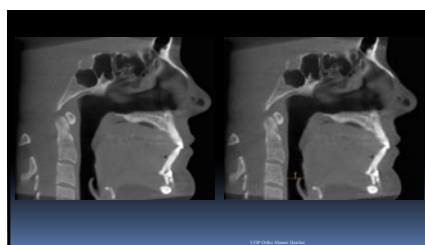
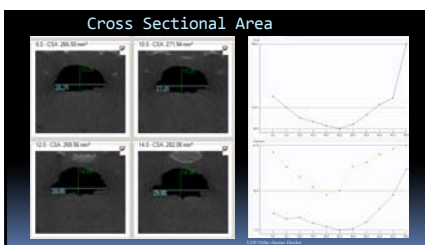
- Volume
- Cross Sectional Area
- Linear Distances

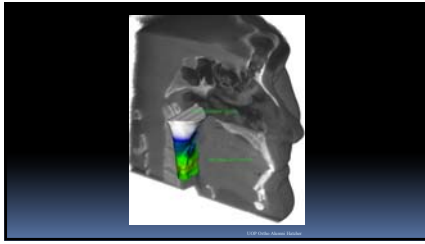
Measurement Error Source

- Soft Ware Accuracy
- Head Position
- Tongue Position
- Tongue Motion



Map Region of Interest (ROI) 3dMD

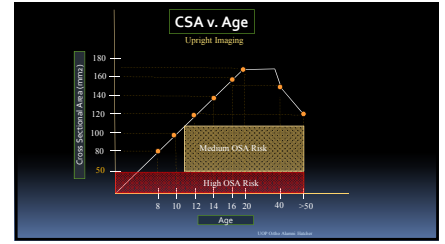




Airway: Role of Imaging

- Airway Imaging Can Not Confirm Or Exclude OSA
- Imaging Can Help Understand Airway Anatomy (Phenotype)
 - Identify Potential Obstruction Sites
 - Evaluate Airway Support Structures

UPP © John A. Stankovic



Airway Resistance and Flow

- Poiseuille's Law**
 - $R = 8nl / \pi r^4$
 - R = Resistance
 - n = Viscosity
 - l = phi
 - r = Radius
- Ohm's Law**
 - $V = P_{inlet} - P_{outlet} / R$
 - V = Flow
 - P = Pressure
 - R = Resistance

↓ Radius = ↑ Resistance = ↑ Pressure Gradient
↑ Respiratory Effort

UPP © John A. Stankovic

Airway Dimensions and OSA

- Retroglossal and Retropalatal Space Predictive of RDI

Cross Sectional Area	OSA Probability
< 52 mm²	High
52 - 100 mm²	Medium
> 100 mm²	Low

Chen M, Wang CR, Shi W, Wang PC. Use of 3-dimensional computed tomography scan to measure upper airway volume and predict sleep-disordered breathing severity. Chin J Otorhinolaryngol Head Neck Surg. 2002; 17(4): 330-32

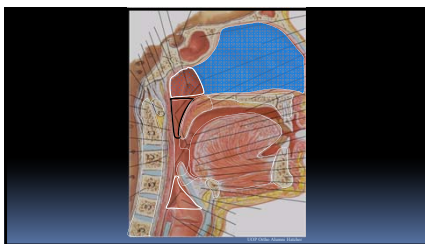
UPP © John A. Stankovic

3d CBCT Trends

	OSA	Control
BMI	29.5	23.1
Volume	4868 mm³	6051 mm³
Smallest Area	4.6 mm²	14.7 mm²
AP	4.6 mm	7.8 mm
Lateral	11.6 mm	16.2 mm

Ogawa T, Ryan Evans, W Shindoh, Glenn Cook, Otolaryngol. Jan 2007

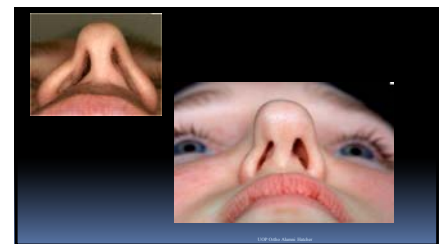UPP © John A. Stankovic

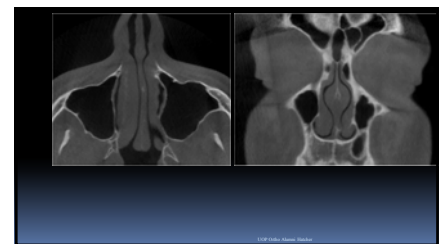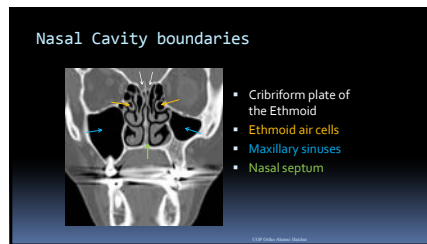
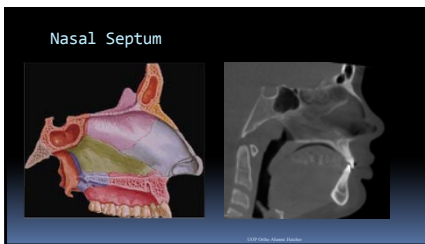
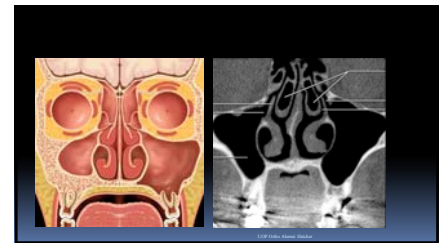
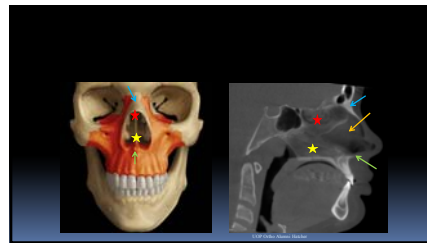
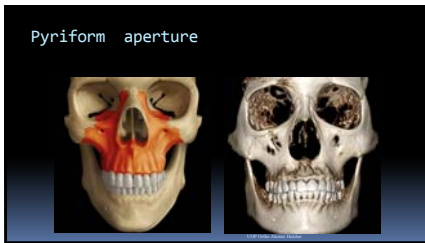
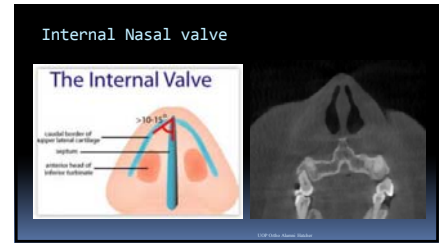
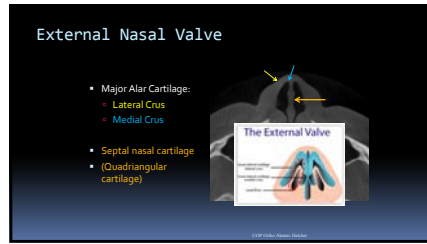
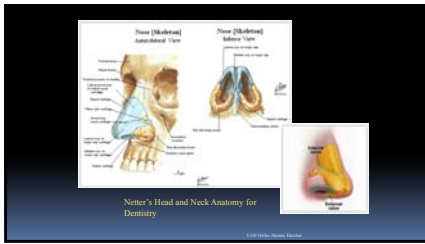


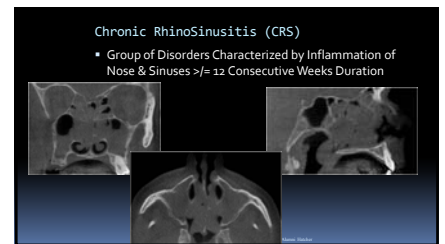
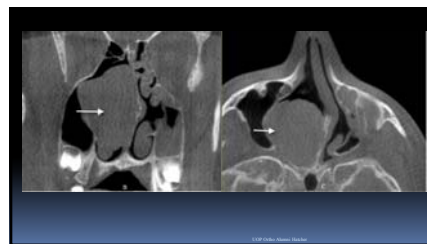
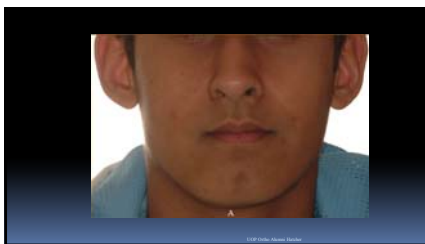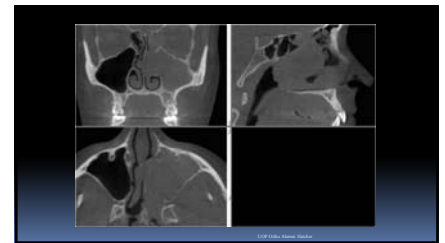
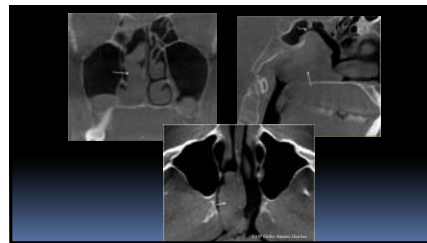
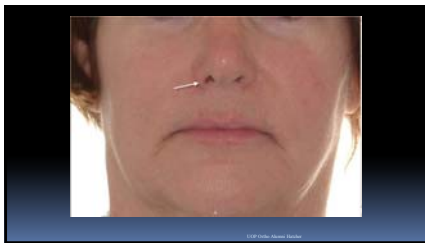
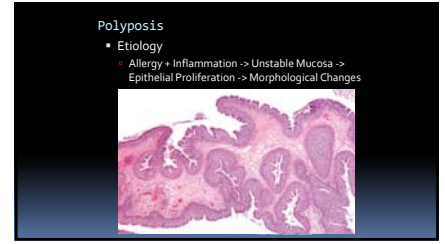
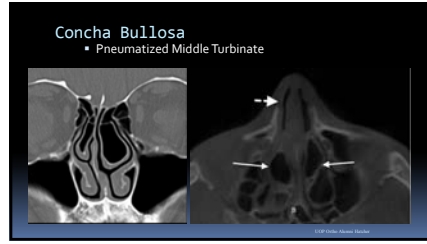
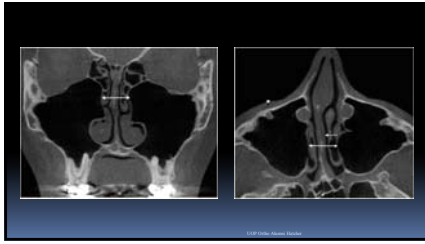
Nasal Valves

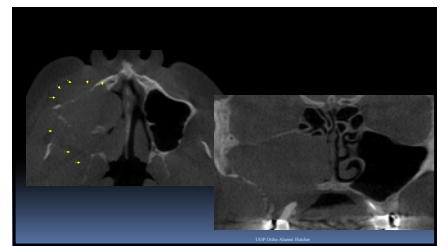
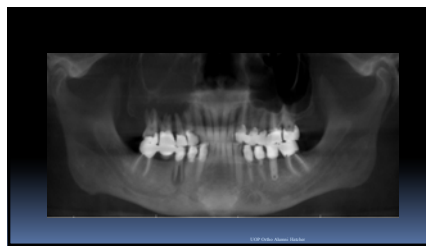
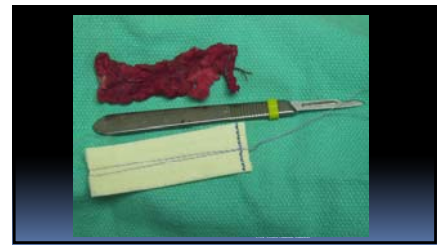
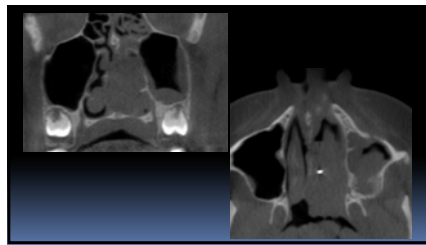
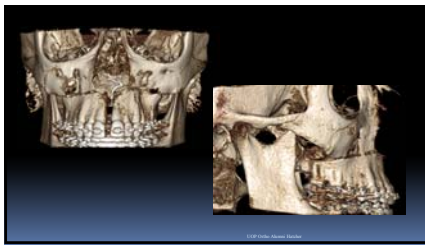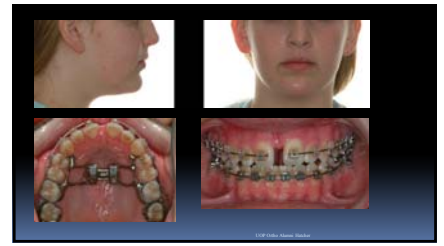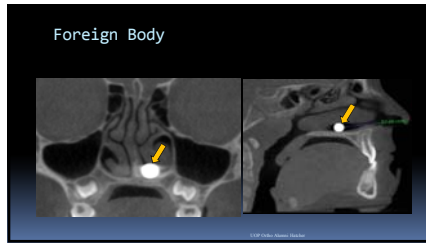
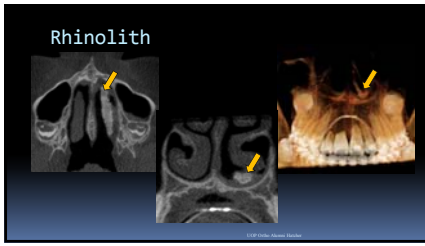- External Nasal Valve
- Internal Nasal Valve

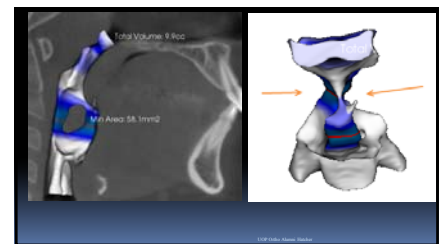
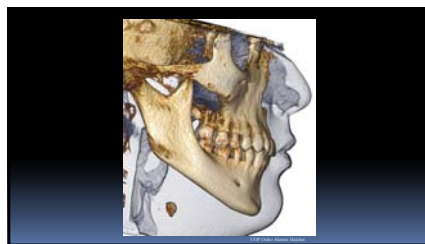
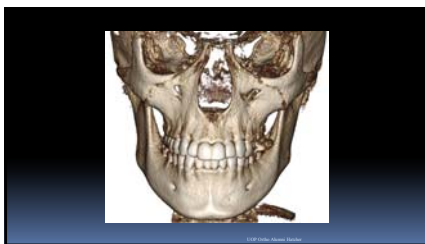
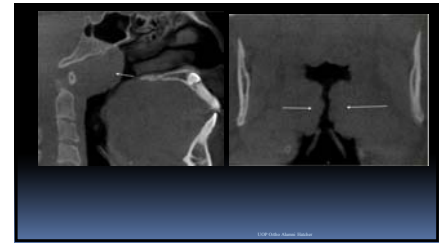
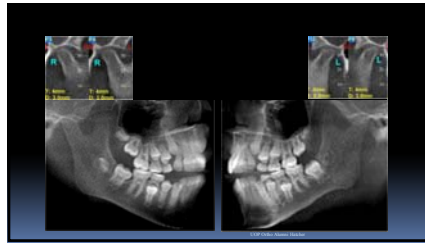
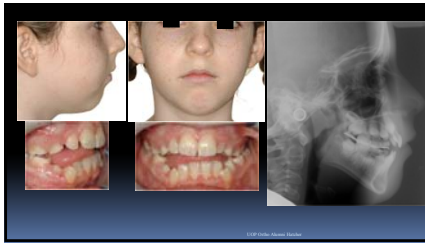
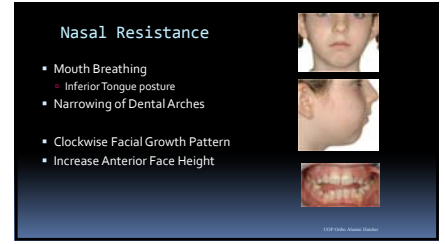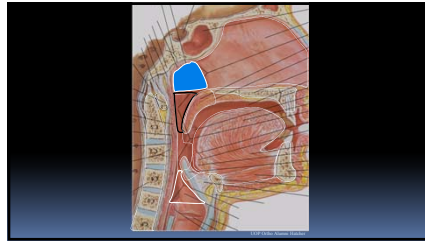
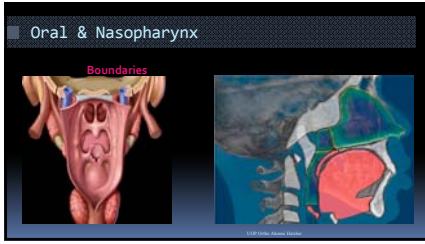
UPP © John A. Stankovic

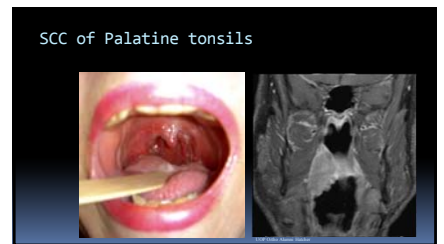
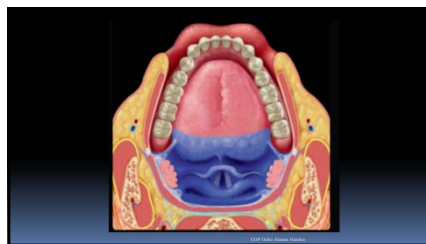
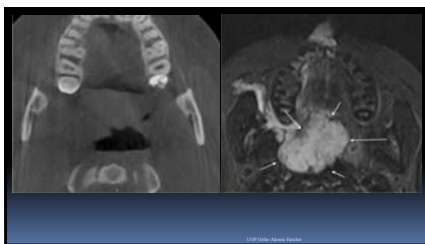
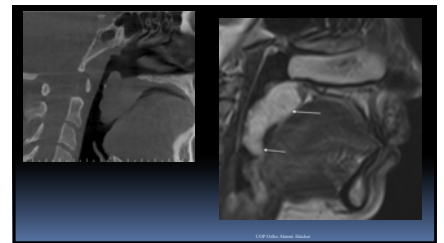
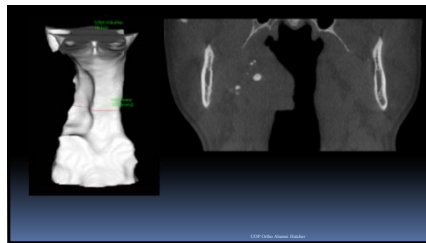
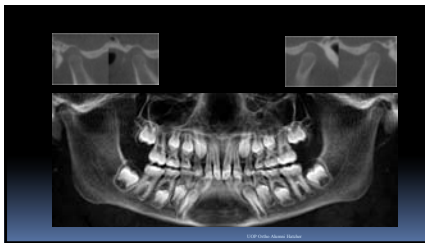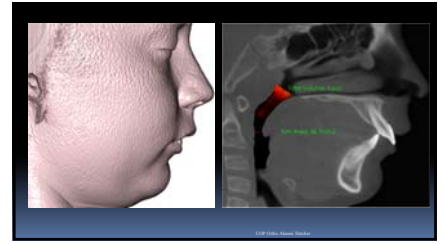
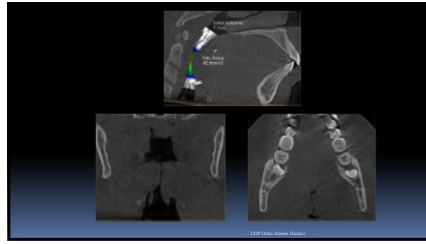
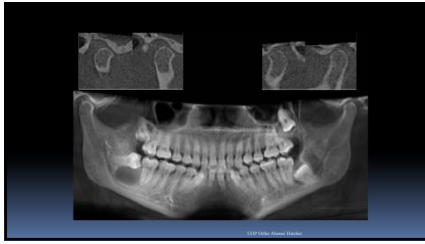


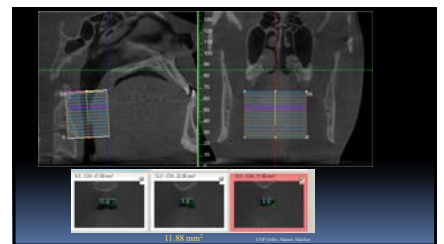
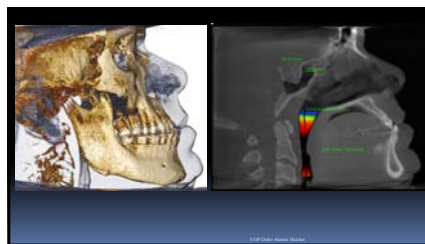
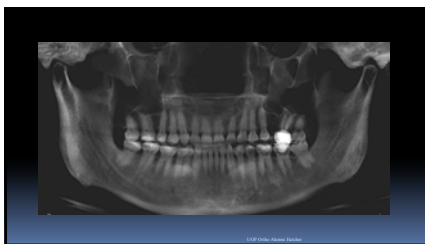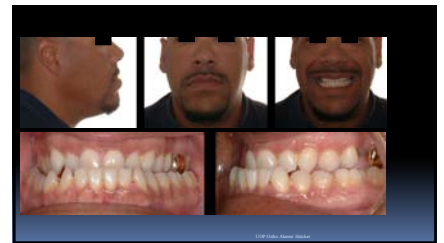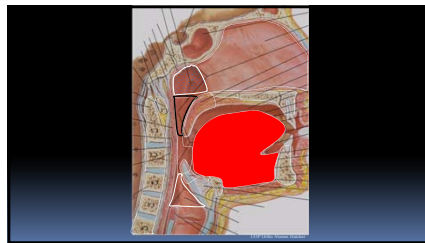
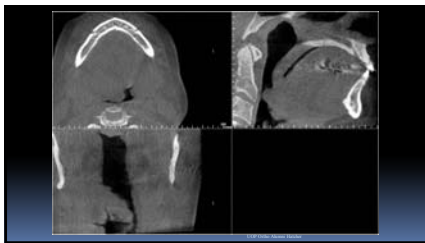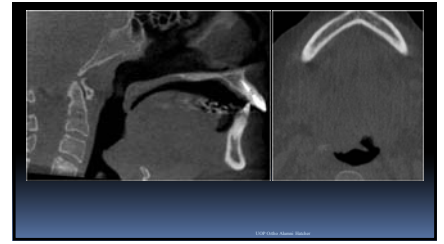
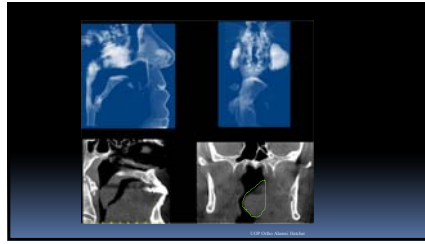
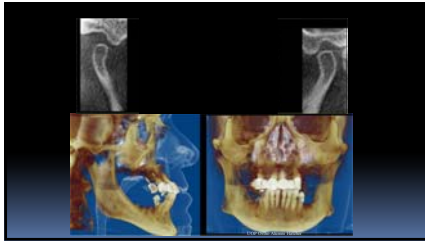






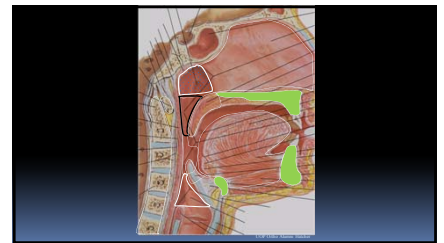
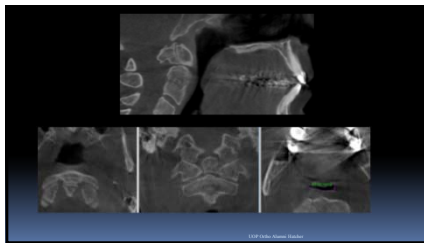
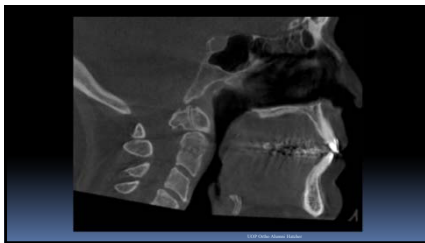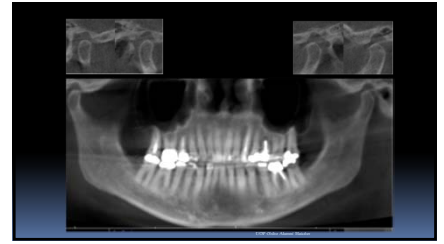
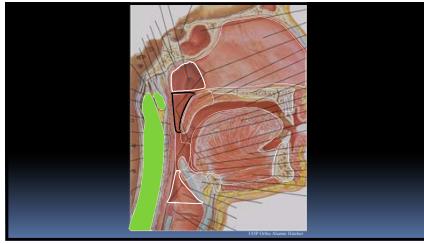




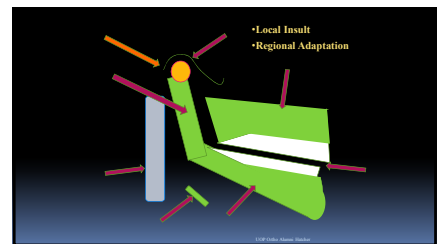
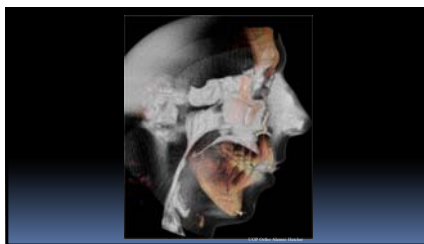


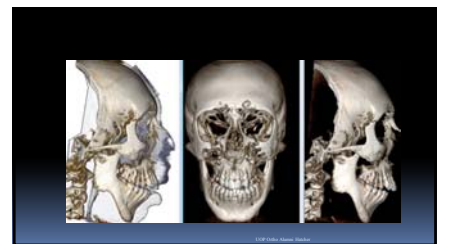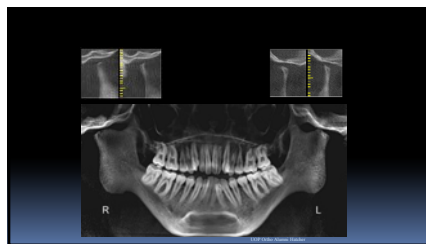
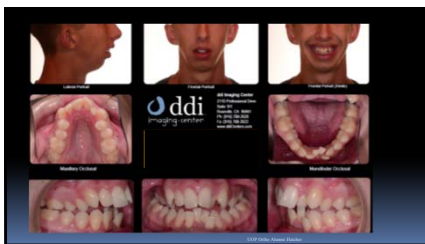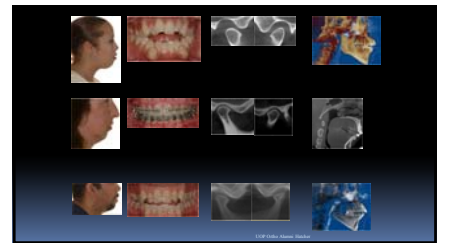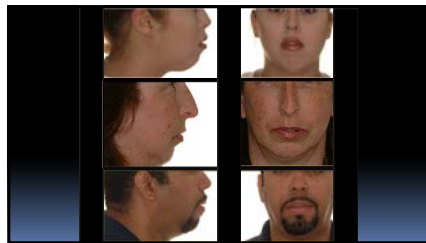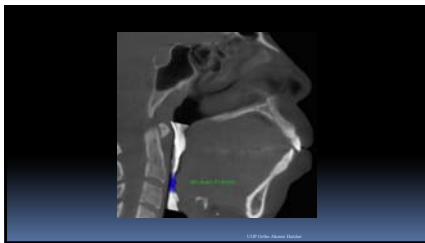
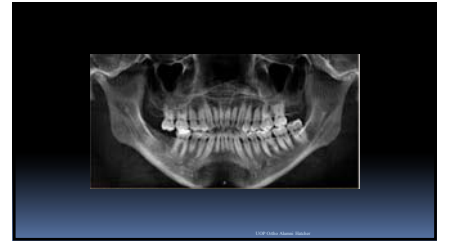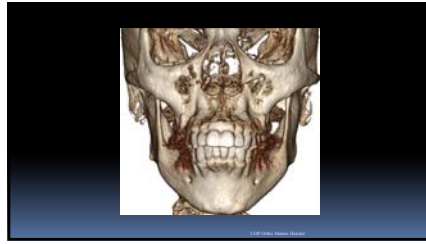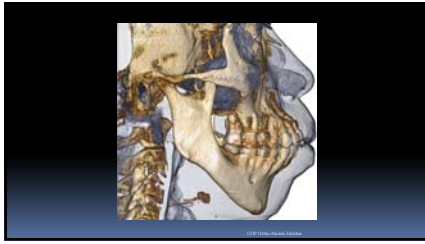
Support Structures for Airway

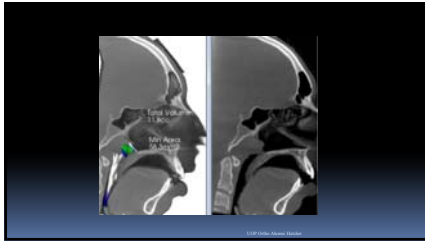
- Cervical Spine
- Jaws




Facial Growth Patterns

Two lateral cephalometric radiographs (X-rays) of the skull. The first image shows a normal growth pattern, and the second image shows a different growth pattern. Yellow arrows indicate the direction of growth.





Conclusions



- Imaging provides a Support Role in SDB
- Granular Dx. Leads to a Tailored Treatment
- Accurate Dx. Leads to the Best Treatment Outcomes
- Consider Airway from External Nasal Valves to Trachea
- Consider Support Structures for Airway
 - Jaws
 - Spine
 - Tongue
 - Soft Palate

